

**Case Report****Primary Retroperitoneal Hydatid Disease: A Rare Case Report**Junaid Alam^{1*}, Mohammad Aslam², Imad Ali^{3*}, Aditya Varshney⁴, Manisha Singh⁵¹Assistant Professor Department of General Sugery, Jawaharlal Nehru Medical College and Hospital; AMU Aligarh²Professor, Department of General Sugery, Jawaharlal Nehru Medical College and Hospital, AMU, Aligarh³Junior Resident Department of General Sugery, Jawaharlal Nehru Medical College and Hospital AMU, Aligarh⁴Junior Resident Department of General Sugery, Jawaharlal Nehru Medical College and Hospital; AMU, Aligarh⁵Junior Resident Department of General Sugery, Jawaharlal Nehru Medical College and Hospital; AMU, Aligarh**ARTICLE INFO:****ABSTRACT****Article history:**

Received: 12 September, 2017

Received in revised form: 25 September, 2017

Accepted: 18 October, 2017

Available online: 30 October, 2017

Keywords:

Hydatidosis

Hydatid cyst

Rare site

Retroperitoneal

Hydatid disease or hydatidosis (HD) is caused by the larval stage of parasite *Echinococcus granulosus* (dog tapeworm). Primary retroperitoneal hydatid cyst is extremely rare and only occasional case reports have appeared. Surgery remains the mainstay of treatment with postoperative pharmacological administration of anthelmintics. We report a case of primary retroperitoneal hydatid cyst in 35 year-old male patient at our centre.

1. Introduction

Hydatid disease or hydatidosis (HD) is a greek term which is caused by the larval stage of parasite *Echinococcus granulosus* (dog tapeworm). There are 2 main types of *Echino coccus* infections, caused by *E. granulosus* and *E. multilocularis*. The most common form in humans is caused by *E. granulosus*. Infestation with larval stages of dog tapeworms can result in encystation in various organs. The commonly involved organs include the liver (75%) and lungs (15%), while the remaining 10% occurs in other body organs including spleen, kidney, pancreas, peritoneum, retroperitoneum, central nervous system, soft tissues, and the breast[1-2]. Theoretically, it can occur at any site except teeth, hair, and nails[3]. Primary retroperitoneal hydatid cyst is extremely rare and only occasional case reports have appeared since Lockhart and Sapinza first reported this entity in 1958[4]. There are no specific local or general symptoms and signs of HD, and it is often diagnosed as an incidental finding or unless the cyst grows and produces symptoms due to pressure, ruptures to the pleural or peritoneal cavity, secondary infection, or an allergic reaction[5]. The combination of clinical history, imaging findings, and serologic test results usually aids in the diagnosis[1-2]. Histopathological examination of hydatid cysts is confirmatory and shows laminated membranes, which are eosinophilic (Hematoxylin and Eosin staining) and are characterized by the presence of inflammatory cells in the cyst wall. The seepage of fluid causes inflammatory reactions or granulomatous inflammation with histiocytes and giant cells, supporting the diagnosis of hydatidosis. Surgery remains the mainstay of treatment with the primary

principles, including cyst excision without disrupting the cyst integrity as to avoid rupture and formation of multiple cysts. Rarity of this entity prompted us to report this case. We report herein a case of hydatid disease of the retroperitoneum without any other organ involvement.

2. CASE REPORT

A 35 year old male patient was admitted in our surgical department with a history of large abdominal swelling which was progressively increasing for last 20 years. Initially it was located to right lumbar region only. Patient had no abdominal complaints except for dull aching pain due to tense abdomen. Past history was insignificant and systemic examination was normal. Local examination revealed non tender multiple bossilated cystic swellings per abdomen with positive fluid thrill noted over each cystic swelling separately (Figure No. 1).

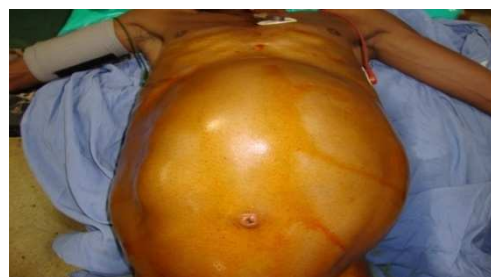

Figure No. 1: Tense distended abdomen showing an appreciable mass

Corresponding Author: Dr. Imad Ali, Junior Resident Department of General Sugery, Jawaharlal Nehru Medical College and Hospital AMU, Aligarh, India; E-mail: imademu@gmail.com

Flexion of the right hip was restricted to some extent. Complete blood count, liver and kidney function tests were normal. ELISA for hydatid was suggestive. Plain X- ray abdomen did not show any specific diagnostic finding. On USG, multiple cystic cavities with characteristic appearance of cyst within cyst was noted (Figure No. 2). The site of origin of cyst could not be made out due to its huge extent. Contrast Enhanced CT scan abdomen revealed a large retroperitoneal cystic mass on the right side and pushing the psoas muscle anteromedially. There was no evidence of similar cystic lesion in liver, lungs or any other organ. Based on the clinical, serological and radiological evidence, a provisional diagnosis of retroperitoneal hydatid cyst was made. Exploratory laparotomy was done which revealed a large cystic cavity with numerous daughter cysts (Figure No. 3). After careful examination intraoperatively , cavity was found to be arising from retroperitoneum pushing the bowel to right iliac fossa and in pelvic cavity. Two more retroperitoneal cavities were identified ,one adjacent to the spleen and another originating from pelvis. Cysts were explored and numerous daughter cyst were enucleated (Figure No. 4). Cavities were flushed with 3% hypertonic saline and povidine iodine solution with marsupialization of the cavities with excision of the redundant portion. Three drains were placed within the cavities & abdomen closed. The patient had an uneventful postoperative recovery and the drain was removed after few days. Histopathology confirmed the diagnosis of *Echinococcus*. Patient was discharged on albendazole 400mg BD for 6 month.

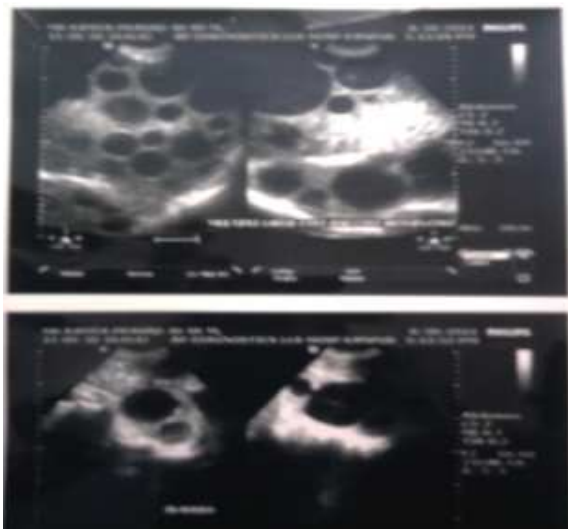


Figure No. 2: USG showing multiple cystic cavities

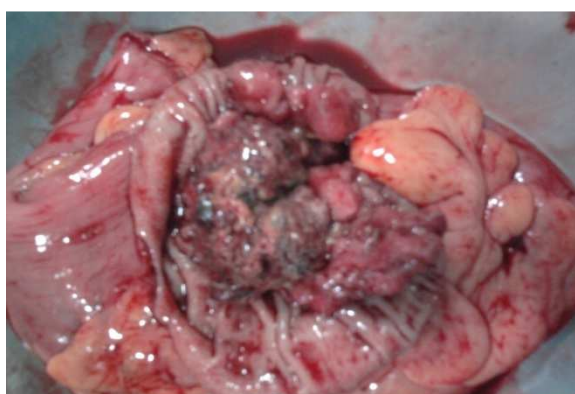

Figure No. 3: Intraoperative picture showing retroperitoneal large cavity with daughter cysts

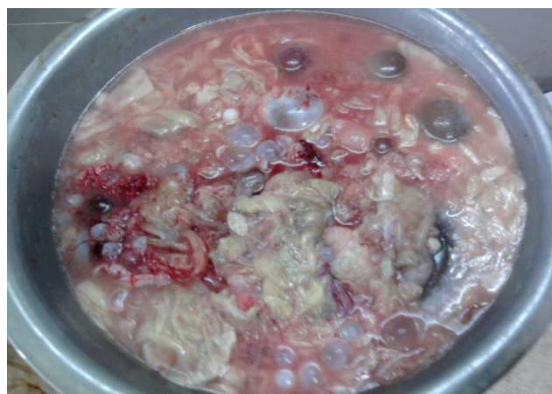

Figure No. 4: Evacuated Hydatid cysts with daughter cysts

3. Discussion

Hydatid disease is the most widespread human cestode infection in the world. In this serious parasitic infection, humans are incidental hosts and acquire the disease as a result of fecal-oral contamination either directly by ingesting the parasite eggs through contact with dogs or indirectly through consuming contaminated water or food. HD is caused by the cystic stage of infestation by *Echinococcus granulosus*. A hydatid cyst consists of three layers: the outermost layer is adventitia, the intermediate is laminated membrane (endocyst), and the innermost is the germinal layer[1-2]. Germinal epithelium is the only living part of a hydatid cyst. Hydatid cysts are characterized as cystic lesions with clear boundaries, which can be observed in all parts of the body. These cystic lesions grow gradually and increase in number by means of the daughter cysts that they produce. Various modes of spread have been suggested to explain the escape of liver and lung involvement-via lymphatics or via veno-venous shunts within the liver and in the space of Retzius[6-7]. Dew and Waddel had favored airborne transmission and direct implantation of the embryo in the bronchial mucosa as another possible mode of entry[8-9]. This raises the possibility of an embryo of the parasite entering a venule after penetrating the bronchial mucosa and reaching the left side of the heart to involve other sites and thus bypassing the lung. But this remains largely theoretical and needs to be proved. There are no specific local or general symptoms and signs of HD, and most cases are diagnosed following incidental findings on radiographic examination for unrelated complaints. Routine blood tests are generally normal but eosinophilia occurs in a quarter of cases. Immunodiagnostic tests may be useful for diagnosis. Serological tests contribute to the diagnosis. Immunoglobulin G antibody detection by ELISA has a sensitivity of 95% and specificity of 94%. The sensitivity of indirect hemagglutination test has been found to be 87.5%[10-11].

Therapy for extra hepatic echinococcal disease is based on considerations regarding the size, location and manifestations of the cysts, and the overall health status of the patient. Asymptomatic small cysts once diagnosed can be treated with antihelminthic drugs, administered for 28 days in one to eight repeating cycles, separated by drug-free intervals of 2-3 weeks[12]. This entity adds to the primary extrahepatic hydatid cysts. For symptomatic or large hydatid retroperitoneal cysts, surgery, when feasible, is the principal method of treatment. Surgical treatment can be either radical or conservative. Total cystectomy, whenever

possible, is the gold standard.

The single most factors which prompted us to report this case in literature is that one must have a high index of suspicion and rule out hydatid cyst in every case of retroperitoneal cystic swelling under evaluation, especially in endemic areas, and therefore take adequate steps in order to avoid a serious complication like anaphylaxis. Excision of the cyst may not be possible always, because of dense adhesions and presence of other vital structures around. Hence it is preferable to evacuate the parasite and excise the redundant portion of the pericyst leaving the rest of the cavity open or to drain it externally with a wide bore drain. Accurate diagnosis of hydatid disease is of utmost importance, as it facilitates proper surgical planning and intraoperative measures to prevent spillage, which can only be assumed when there is already a preoperative suspicion[13-16].

In conclusion, retroperitoneal hydatosis is a rare phenomenon, which should be always considered in the differential diagnosis, especially in areas where echinococcosis is endemic. Detailed preoperative evaluation with MRI and CT scan is necessary in localizing the lesion and planning the surgical approach[9-10]. Postoperative pharmacological administration of anthelmintics, commonly albendazole, is advised due to easy absorption and better efficiency according to WHO recommendations.

4. CONCLUSION

Hydatidosis (HD) is caused by the parasite *Echinococcus granulosus*. Infestation with larval stages of dog tapeworms can result in encystation in various organs. The combination of clinical history, imaging findings, and serologic test results usually aids in the diagnosis. Surgery remains the mainstay of treatment with the primary principles, including cyst excision without disrupting the cyst integrity as to avoid rupture and formation of multiple cysts. One must have a high index of suspicion and rule out hydatid cyst in every case of retroperitoneal cystic swelling under evaluation, especially in endemic areas, and therefore take adequate steps in order to avoid a serious complication.

REFERENCES

[1]. Engin G., Acunas B., Rozanes I., Acunas G., Hydatid disease with unusual localization, *Eur. Radiol.* 2000;10:1904-12.
 [2]. Kiresi DA., Karabacakoglu A., Odev K., Karakose S., Uncommon locations of hydatid cysts, *Acta Radiol* 2003;44:622-36.
 [3]. Hamamci EO., Besim H., Korkmaz A., Unusual

locations of hydatid disease and surgical approach, *ANZ. J. Surg.* 2004;74: 356-60.

[4]. Lockhart J., Sapinza VC., Primary retroperitoneal hydatidosis, *Bol. Soc. Cir.* . 1956; 27:2-3:290-303.
 [5]. Prousalidis J., Tzardinoglou K., Sgouradis L., Uncommon sites of hydatid disease, *World J. Surg.* 1998;22:1:17-22
 [6]. Barret NR., The anatomy and the pathology of multiple hydatid cysts in the thorax, *Ann. R. Coll. Surg. Engl.* 1960;26:6:362-79.
 [7]. McPhail JL., Arora TS., Intrathoracichydatid disease, *Chest* 1967;52:6:772-81.
 [8]. Dew HR., Hydatid Disease-Its pathology, Diagnosis and Treatment, 1st ed. Sydney: Aust. Med. Pub. Com Ltd.; 1928: 304-15.
 [9]. Waddle N., Pulmonary hydatid disease; a review of 478 cases reported in the Louis Barnett hidatid registry of the Royal Australian College of Surgeons, *Aust. N. Z. J. Surg.* 1950;19:4::273-8.
 [10]. Shambesh MA., Craig PS., Macpherson CN., An extensive ultrasound and serologic study to investigate the prevalence of human cystic echinococcosis in northern Libya, *Am. J. Trop. Med. Hyg.* 1999;60:3:462-8.
 [11]. Wen H., Craig PS., Immunoglobulin G subclass responses in human cystic and alveolar echinococcosis, *Am. J. Trop. Med. Hyg.* 1994;51:6:741-8.
 [12]. Karavias DD., Vagianos CE., Kakkos SK., Peritoneal hepatic abdominal Hydatidosis, *Int. J. Surg.* 2005;3:2:125.
 [13]. Ismail MA., Al-Dabagh MA., Al Janabi TA., The use of computerized axial tomography (CAT) in the diagnosis of hydatid cysts, *Clin. Radiol.* 1980;31:3::287-90.
 [14]. Mukherjee S., Nigam M., Saraf JC., Primary retroperitoneal hydatid cyst, *Br. J. Surg.* 1973;60:11:916-8.
 [15]. Balik AA., Celebi F., Basglu M., Intra-abdominal extra hepatic echinococcosis, *Surg. Today* 2001;31:10:881-4.
 [16]. Daali M., Hssaida R., Zoubir M., Peritoneal hydatidosis: a study of 25 cases in Morocco, *Sante* 2000;10:4:255-60.

Source of support: Nil, Conflict of interest: None Declared